

SONOGRAPHIC EVALUATION OF YOLK SAC

Laly Jose, Nanditha Abdul Latheef

Abstract— Yolk sac is the most important conceptional structure evaluated sonographically in first trimester. Yolk sac can be detected early by transvaginal sonography when the mean gestational sac diameter is 5-6mm. The important benefit of sonographic evaluation of yolk sac is confirmation of intra uterine pregnancy. The present study is aimed at identifying various characteristics of yolk sac in first trimester pregnancy complications by transvaginal ultrasound evaluation. Antenatal patients with bleeding per vagina or abdominal pain or both in first trimester and diagnosed as cases of threatened abortion, missed abortion, incomplete abortion or suspected ectopic gestation were included in the study. Among 133 gestational sacs present by transvaginal sonography, there were yolk sacs in 106 patients (79.7%) and yolk sac was absent in 27 patients (20.3%) with gestational sac MSD >8mm. 27 cases had no yolk sac when the gestational sac diameter was greater than 8mm. Among them 25 cases with the absence of yolk sac and fetal pole when the MSD >8mm ended up in complications. However there were 2 cases with no yolk sac but a normal appearing gestational sac and fetal pole with good cardiac activity till 10 to 11 weeks which were subsequently lost for further follow up. The association between the presence of the yolk sac and the final ultrasound diagnosis was significant ($p < 0.001$). Assessment of yolk sac should be part of complete first trimester sonographic examination. An abnormality in sonographic appearance of yolk sac can predict subsequent embryonic health or abnormalities. There for accurate recognition of normal and abnormal sonographic findings related to yolk sac can be used to anticipate the course of pregnancy.

Index Terms— Embryonic health, Pregnancy, Sonography, Transvaginal ultrasound, Yolk sac.

1 INTRODUCTION

Yolk sac is the most important conceptional structure evaluated sonographically in first trimester. Yolk sac can be detected early by transvaginal sonography when the mean gestational sac diameter is 5-6mm. The important benefit of sonographic evaluation of yolk sac is confirmation of intra uterine pregnancy [1, 2]. It has been hypothesized that sonographic features related to shape, size and internal structure of yolk sac can be associated with gestational outcome [3]. Normally the yolk sac appears as circular structure with anechoic center surrounded by a uniform well defined echogenic wall. Usually inner diameter of yolk sac measures 3 mm - 5 mm. The yolk sac size progressively increases from beginning of fifth week of gestation to end of tenth week of gestation. Afterwards yolk sac decreases gradually in size [4].

The present study is aimed at identifying various characteristics of yolk sac in first trimester pregnancy complications by transvaginal ultrasound evaluation.

MATERIALS AND METHODS

Antenatal patients who presented to causality or Obstetrics unit of Karakonam Medical college either with bleeding per vagina or abdominal pain or both in first trimester and diagnosed as cases of threatened abortion, missed abortion, incomplete abortion or suspected ectopic gestation for a period of 1 ½ years from August 2010 - January 2012 were

- Dr. Laly Jose, Professor of Radiodiagnosis, SM CSI Medical College, Karakonam P O, Thiruvananthapuram- 695504
- Dr. Nanditha Abdul Latheef, Associate professor of Radiodiagnosis, SM CSI Medical College, Karakonam P O, Thiruvananthapuram- 695504

included in the study.

Inclusion criteria

All first trimester pregnancies with bleeding per vagina and or abdominal pain who were referred for sonography from Dept. of Obstetrics and Gynecology department of SMI CSI Medical College, Karakonam.

Exclusion Criteria

Cases where patients were not willing for transvaginal Ultrasound.

Ethical clearance was obtained from institution review board. The study was done using Siemens Sonoline G 50 transabdominal USS using 3 to 5 MHz convex transducer followed by transvaginal uss using 5 -10 MHz endovaginal transducer. Patient was followed up as indicated or upto 20 weeks of gestation. Detailed evaluation of yolk sac which included size, shape, echogenicity and presence of calcification was performed.

OBSERVATION AND RESULTS

Yolk Sac Presence

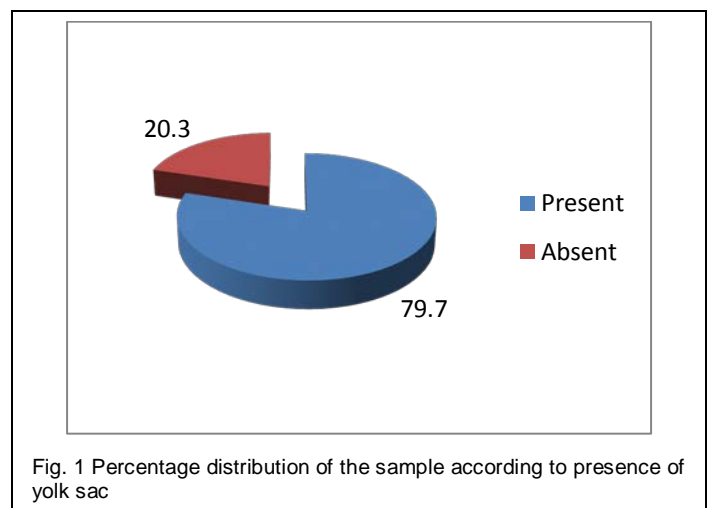


Fig. 1 Percentage distribution of the sample according to presence of yolk sac

Diagram shows that in the total 133 gestational sacs present by transvaginal sonography, there were yolk sacs in 106 patients (79.7%) and yolk sac was absent in 27 patients (20.3%) with gestational sac MSD >8mm.

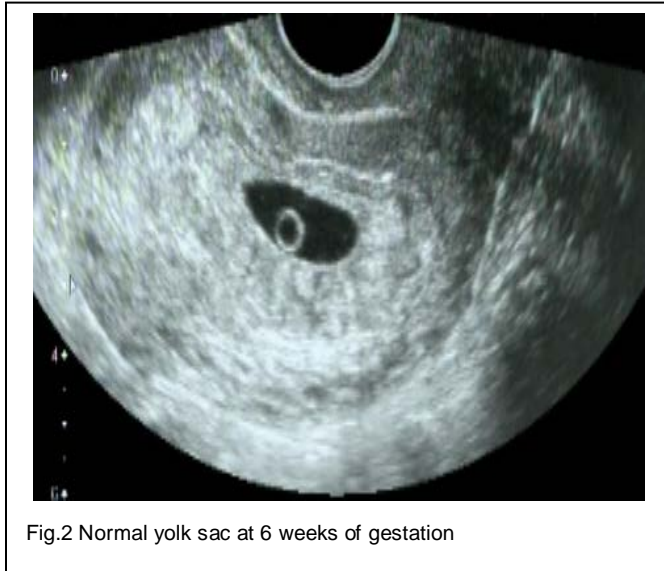

Fig.2 Normal yolk sac at 6 weeks of gestation

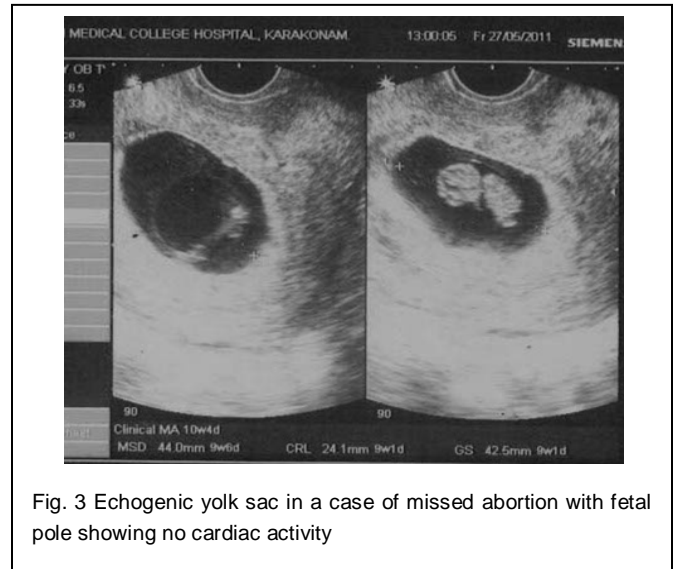


Fig. 3 Echogenic yolk sac in a case of missed abortion with fetal pole showing no cardiac activity

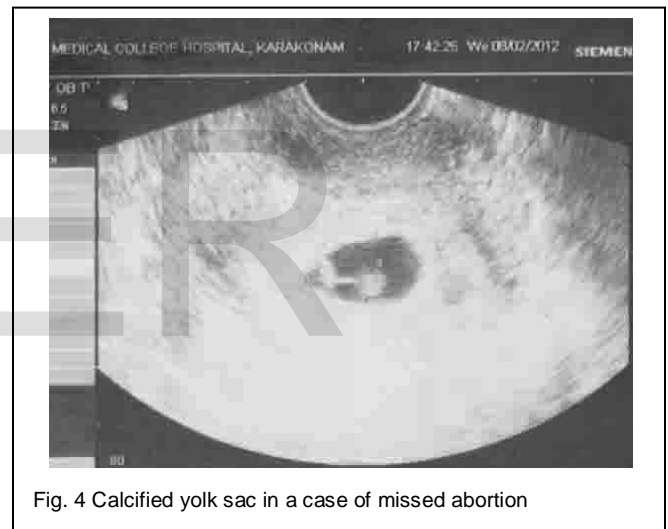


Fig. 4 Calcified yolk sac in a case of missed abortion

TABLE 1

ASSOCIATION BETWEEN THE PRESENCE OF THE YOLK SAC AND FINAL OUTCOME ON FOLLOW UP WITH MSD >8MM

Presence of yolk sac	Normal pregnancy (normal)		Complicated pregnancy (Abnormal)		Total	Chi-sq	P value
	N	%	N	%			
Yes	69	65.1	37	34.9	106	28.8	0.0001
No	2	7.41	25	92.6	27		
Total	71		62		133		

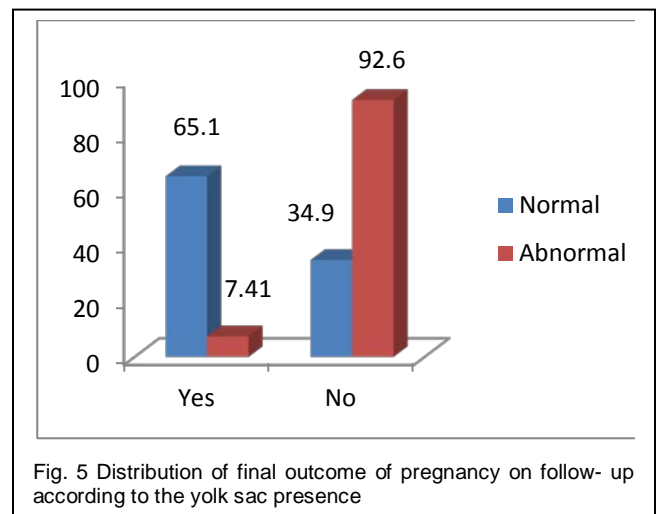


Fig. 5 Distribution of final outcome of pregnancy on follow-up according to the yolk sac presence

27 cases had no yolk sac when the gestational sac diameter was greater than 8mm. Among them 25 cases with the absence of yolk sac and fetal pole when the MSD >8mm ended up in complications.

However there were 2 cases which no yolk sac but a normal appearing gestational sac and fetal pole with good cardiac activity till 10 to 11 weeks which were subsequently lost for further follow up.

The association between the presence of the yolk sac and the final ultrasound diagnosis was significant ($p < 0.001$).

Abnormality of yolk sac

TABLE 2

PERCENTAGE DISTRIBUTION OF THE SAMPLE ACCORDING TO ABNORMALITY OF YOLK SAC

Appearance	No. of pregnant woman	Percentage
Normal	93	87.7
Echogenic	4	3.7
Small	4	3.7
Large	2	1.9
Calcified	3	2.8
Total	106	100

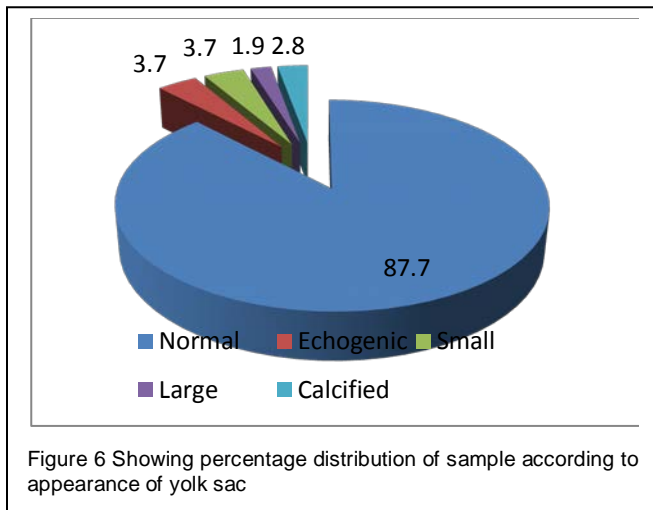


Figure 6 shows that about 88% of the visualized yolk sac were normal, in 3.7% it was echogenic, in 4% small, 1.9% large and 2.8% calcified. From this it was seen that most of the subjects had a normal yolk sac.

TABLE 3

ASSOCIATION BETWEEN ABNORMALITY OF THE YOLK SAC AND FINAL OUTCOME OF PREGNANCY ON FOLLOW UP

Presence of yolk sac	Normal pregnancy (normal)		Complicated pregnancy (Abnormal)		Total	Chi-sq	P value
	N	%	N	%			
Normal	65	69.8	28	30.2	93	7.6	0.006
Abnormal	4	30.7	9	69.3	13		
Total	69		37		106		

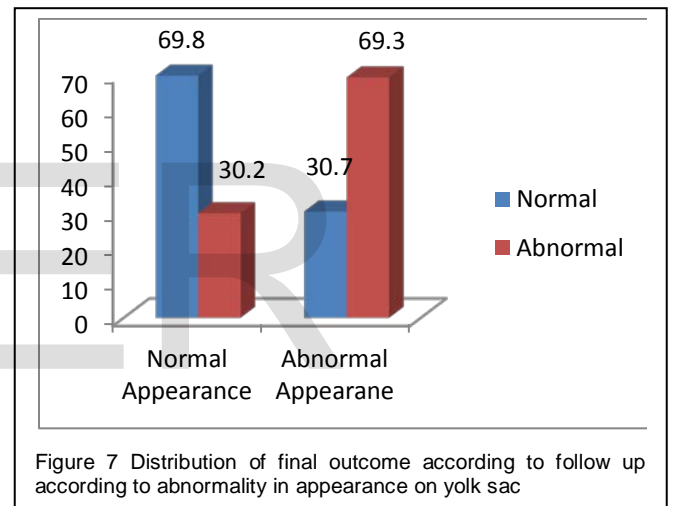


Table 3 and figure 7 shows 69.3% of patients having abnormally appearing yolk sac on ultrasound examination ended up in complications whereas only 30.2% of patients having normal appearing yolk sac had complications. This association was seen to be statistically significant.

DISCUSSION

In 106 patients (79.7%) the yolk sac was present and in 27 patients (20.3%) it was not present. 25 cases with absence of yolk sac when the MSD > 8mm by TVS and which had no fetal pole among the total 27 cases having no yolk sac had an abnormal outcome on follow up.

Cho FN et al [5] conducted a study in which Transvaginal ultrasonography was performed in 111 normal singleton pregnancies, 25 anembryonic gestations, and 18 missed abortions. The relationship between yolk sac and gestational sacs in normal pregnancies was depicted. The ultrasound findings regarding yolk sac in cases of pregnancy loss were also recorded. It was seen in this study that as the pregnancy

matures, a yolk sac becomes visible on transvaginal scan by 8mm MSD or by 20mm MSD on transabdominal scan. According to Varela et al [6] in transvaginal Sonography, absence of yolk sac in presence of an embryo is always abnormal and in general is associated with subsequent fetal loss.

Appearance of yolk sac

In about 88% the yolk sac was normal, in 3.7% it was echogenic, in 3.7% small, 1.9% large and 2.8% calcified. From this it was seen that most of the subjects had a normal yolk sac. Among the abnormal yolk sacs 69.3% went into complications whereas 30.2% only went into complications among the pregnant women who had normal yolk sac. This association was seen to be statistically significant. Among the 4 cases having a small yolk sac (<2mm), 3 were seen to continue as normal pregnancy. Only one went into spontaneous expulsion. The 3 patients with calcified yolk sac were diagnosed to have missed abortion and went into spontaneous expulsion.

An earlier study [7] with certain limitations suggests that yolk sac diameter of 2mm or less may be associated with adverse outcome in pregnancy with gestational age of 8-12weeks. Echogenic yolk sacs were mostly seen in an embryonic gestation (3 out of 4). A single case of missed abortion was seen with an echogenic yolk sac. Also among the large yolk sacs (>5mm), one case continued as normal pregnancy. The other case went into spontaneous expulsion even in the presence of an embryo with good cardiac activity.

In Cho FN et al [5] study also it was seen that the largest yolk sac in viable pregnancies was 8.1mm. In anembryonic gestations an absent yolk sac, an irregular shaped yolk sac and a relatively large yolk sac was seen (>95% upper confidence limits, in 11 cases). A very large yolk sac may exist in normal pregnancy as was seen in our study also. Thus they concluded that when embryonic heartbeats exist, the poor quality and early regression of a yolk sac are more specific than the large size of a yolk sac in predicting pregnancy loss. When an embryo is undetectable, a relatively large yolk sac, even of normal shape, may be an indicator of miscarriage. According to Berdabl et al [8] a yolk sac diameter of greater than 5mm is associated with increased risk of spontaneous abortion.

According to Sinan Tan et al [9] assessment of yolk sac should be part of a complete first trimester sonographic examination. An abnormality in the sonographic appearance of a yolk sac can predict subsequent embryonic death or abnormalities.

CONCLUSION

Assessment of yolk sac should be part of complete first trimester sonographic examination. An abnormality in sonographic appearance of yolk sac can predict subsequent embryonic health or abnormalities. There for accurate recognition of normal and abnormal sonographic findings related to yolk sac can be used to anticipate the course of pregnancy.

REFERENCES

- [1] Carol MR, Stephane RW, Charboneau IW, Debord FL; Diagnostic ultrasound Philadelphia, Elsevier Mosby -2011.
- [2] Jauniaur E, Johns J, Burton GJ. The role of ultrasound imaging in diagnosing and investigating early pregnancy failure. *Ultrasound obstet. Gynaecol.* 2005 June 25(6): 613-24.
- [3] Tans, Ipek, Pektas MK, Aoifogu, Teber MA, Karaglanoglu. Irregular sac shape. Is it really associated with increased risk of spontaneous abortion. *Ultrasound. Med.* 2011;30 :31-35.
- [4] Nyberg DA, Mack LA, Horvey D, Wang K. Value of yolk sac in evaluating early pregnancy. *J. Ultrasound Med.* 1988; 7:129-133.
- [5] Cho FN, Chen SN, Tai MH, Yang TL. The quality and size of yolk sac in early pregnancy loss. *Aust N Z J Obstet Gynaeco.* 2006 Oct. 46(5):413-8.
- [6] Varelas FK, Prapas NM, Liang RI, Prapas IM, Makedas GA. Yolk sac size and embryonic heart rate as prognostic factors of first trimester pregnancy outcome. *Europ. J. Obstet. Gyanecol. Reprod.* 2008; 138: 10-13.
- [7] Green JJ, Hobbins JC. Abdominal ultrasound examination of first trimester fetus: *Am J Obstet. Gyanecol.* 1988; 159: 155-167.
- [8] Berdabl DM, Blaine J, Van Voorbis B, Dokras A. Detection of enlarged yolk sac on early ultrasound is associated with adverse pregnancy outcomes. *Fertili. Steril* 2010; 94 : 1535-37.
- [9] Sinan Tan MD, Mine Kanat Dektas, Halil Arslan; Sonographic evaluation of yolk sac. *Journal of ultrasound in medicine.* January, 2012 ; Vol. 31: 87-95.